Update for Pathologists on Idiopathic Interstitial Pneumonias

Brandon T. Larsen, MD, PhD; Thomas V. Colby, MD

• ***Context.***—**Idiopathic interstitial pneumonias are a subset of diffuse pulmonary interstitial diseases classified by international consensus in 2002 as idiopathic pulmonary fibrosis, nonspecific interstitial pneumonia, cryptogenic organizing pneumonia, acute interstitial pneumonia, respiratory bronchiolitis interstitial lung disease, desquamative interstitial pneumonia, and lymphoid interstitial pneumonia. Each is associated with a characteristic histopathologic pattern. In 2011, updated consensus guidelines were released for diagnosis and management of idiopathic pulmonary fibrosis. The entire group of idiopathic interstitial pneumonias is currently undergoing refinement, with updates expected in a forthcoming consensus classification. Many of these recent and anticipated changes are relevant to pathologists.**

Objectives.—**To review international consensus guidelines for diagnosis of idiopathic pulmonary fibrosis and other idiopathic interstitial pneumonias and to discuss recent and expected future classification updates.**

Data Sources.—**Published peer-reviewed literature and personal experience of the authors.**

Conclusions.—**Diagnosis of idiopathic interstitial pneumonias by multidisciplinary discussion among clinicians, radiologists, and pathologists is now strongly encouraged. Diagnosis of idiopathic pulmonary fibrosis no longer requires surgical lung biopsy; high-resolution computed tomography is an acceptable surrogate. In the context of clinical trials, pathologists are being asked to assign levels of confidence for histologic diagnosis of usual interstitial pneumonia in patients with idiopathic pulmonary fibrosis. Acute exacerbation of idiopathic pulmonary fibrosis is now accepted and should be considered when acute lung injury is superimposed on a background of usual interstitial pneumonia. The updated classification of idiopathic interstitial pneumonias will include a separate category for rare entities, including lymphoid interstitial pneumonia and idiopathic pleuroparenchymal fibroelastosis.**

(*Arch Pathol Lab Med.* 2012;136:1234–1241; doi: 10.5858/arpa.2012-0225-RA)

The interstitial lung diseases comprise a group of diffuse pulmonary parenchymal diseases that are classified together because of similar clinical, radiologic, physiologic, and/or pathologic manifestations. Classically, these conditions show infiltrates on chest radiographic imaging and display physiologic restriction on pulmonary function tests. The idiopathic interstitial pneumonias (IIPs) represent a subset of interstitial lung diseases that have been classified together for many decades, dating back to 1969 to the original pathologic classification into 5 subtypes by Liebow and Carrington[1] (Table 1); nonspecific interstitial pneumonia was recently accepted (2008) as a subtype.[2,3] Although not every case is truly idiopathic (ie, of unknown cause), these subtypes remain classified together for convenience and because of their general familiarity. Building on Liebow and Carrington's original histopathologic classification is the 2002 American Thoracic Society (ATS)/European Respiratory Society (ERS)[3] international multidisciplinary consensus classification of the IIPs (Table 2). Major milestones for clinicians and pathologists are the 2000 international consensus statement on diagnosis and treatment of idiopathic pulmonary fibrosis (IPF),[4] the 2002 ATS/ERS international multidisciplinary consensus classification of the IIPs,[3] the 2011 ATS/ERS/Japanese Respiratory Society (JRS)/Latin American Thoracic Association (ALAT) evidence-based guidelines for diagnosis and management of IPF,[5] and the forthcoming update to the 2002 ATS/ERS international multidisciplinary consensus classification of the IIPs that is expected later this year. Each of these major consensus statements and its implications for pathologists will be discussed below.

HISTOPATHOLOGIC PATTERNS OF IIPS

The most important IIP pattern is usual interstitial pneumonia (UIP). It is associated with IPF, the most

Accepted for publication June 6, 2012.

From the Department of Pathology, University of Arizona, Tucson, Arizona (Dr Larsen); and the Department of Laboratory Medicine and Pathology, Mayo Clinic, Scottsdale, Arizona (Dr Colby).

Dr Colby has acted as consultant confirming the histologic diagnosis of usual interstitial pneumonia for clinical trials for the following: NIH IPFnet, Actelion, Gilead Sciences, Intermune, Celgene, and Stromedix. Dr Larsen has no relevant financial interest in the products or companies described in this article.

Presented at the Houston Lung Symposium; April 28–29, 2012; Houston, Texas.

Portions of the text were previously published in Raghu G, Collard HR, Egan JJ, et al; ATS/ERS/JRS/ALAT Committee on Idiopathic Pulmonary Fibrosis. An official ATS/ERS/JRS/ALAT statement: idiopathic pulmonary fibrosis: evidence-based guidelines for diagnosis and management. *Am J Respir Crit Care Med*. 2011;183(6):788–824.

Corresponding author: Thomas V. Colby, MD, Department of Laboratory Medicine and Pathology, 13400 E Shea Blvd, Scottsdale, AZ 85252 (e-mail: colby.thomas@mayo.edu).

Downloaded from https://aplm.kglmeridian.com at 2026-03-06 via free access

Table 1. Original 1969 Classification of Chronic Interstitial Pneumonias by Liebow and Carrington[1]
Usual interstitial pneumonia
Desquamative interstitial pneumonia
Bronchiolitis obliterans interstitial pneumonia and diffuse alveolar damage
Lymphoid interstitial pneumonia
Giant cell interstitial pneumonia

common IIP, and the one that carries the worst prognosis and that is often mislabeled with the imprecise designation "pulmonary fibrosis." For the pathologist faced with a possible diagnosis of IIP, UIP is the major pattern to confirm or exclude. In doing so, the pathologist must address the questions: Why is this case UIP? Or why is this case not UIP, and what are the features that allow consideration of an alternate diagnosis?

The histopathologic criteria of UIP are well known and are most commonly encountered in patients with IPF, which was defined in the 2011 ATS/ERS/JRS/ALAT evidence-based guidelines for diagnosis and management of IPF "as a specific form of chronic, progressive, fibrosing interstitial pneumonia of unknown cause, occurring primarily in older adults, and limited to the lungs."[5] IPF is the classic cause of progressive, fibrosing, restrictive lung disease; "the histopathologic hallmark and chief diagnostic criterion is a heterogeneous appearance at low magnification in which areas of fibrosis with scarring and honeycomb change alternate with areas of less affected or normal parenchyma. . . . These histopathologic changes often affect the subpleural and paraseptal parenchyma most severely."[5] Inflammation is generally mild in UIP. Although most scarring is chronic and consists of honeycombing or dense collagenized fibrosis with or without smooth muscle metaplasia, "younger" disease activity may be recognized by the presence of "scattered convex subepithelial foci of proliferating fibroblasts and myofibroblasts (so-called fibroblast foci)."[5] The classic histologic findings of UIP with heterogeneous fibrosis including fibroblast foci are illustrated in Figure 1, A through C. Although most commonly encountered in IPF, the pattern of UIP may also be encountered in connective tissue disease–associated interstitial pneumonia, in chronic hypersensitivity pneumonitis, in familial pulmonary fibrosis, and in some other interstitial lung diseases.

The histologic findings of the other IIPs from the 2002 ATS/ERS international multidisciplinary consensus classification of the IIPs are well known.[3] *Nonspecific interstitial pneumonia* is characterized by relative spatial homogeneity of parenchymal lung involvement (in contrast to the patchy character of UIP) and by temporal homogeneity of the injury (inflammation and/or fibrosis), in contrast to the heterogeneity (recent and old injury) in UIP. *Organizing pneumonia* is characterized by intraluminal organization, with relative preservation of background lung tissue that may show variable degrees of interstitial inflammation, type 2 pneumocyte metaplasia, and some accumulation of airspace macrophages. Intraluminal organization occurs primarily in the alveolar ducts, but may also be seen in alveoli and bronchioles. The term *bronchiolitis obliterans* has been used to describe involvement of the bronchioles, and it was part of the previous name for this lesion (bronchiolitis obliterans organizing pneumonia). When organizing pneumonia occurs as an IIP, it is called *cryptogenic organizing pneumonia*. The most acute IIP is *acute interstitial pneumonia*, which has histologic features of acute and/or organizing diffuse alveolar damage: hyaline membranes and edema in the acute phase, with variable degrees of interstitial and airspace organization in the organizing phase. *Respiratory bronchiolitis–associated interstitial lung disease* is recognized as a smoking-related interstitial lung disease, but is still included as an IIP. The main pathologic findings in respiratory bronchiolitis–associated interstitial lung disease are respiratory bronchiolitis, with lightly pigmented macrophages and mild inflammatory changes that are primarily centered on respiratory bronchioles. *Desquamative interstitial pneumonia* is also associated with smoking in most cases. In contrast to respiratory bronchiolitis–associated interstitial lung disease, desquamative interstitial pneumonia involves much more widespread airspace filling by macrophages, which typically have the tan-brown pigmentation of smoker's macrophages. *Lymphoid interstitial pneumonia* is a rare form of IIP. It is dominated histologically by cellular infiltrates (by definition, polyclonal and inflammatory), which may be diffuse and interstitial and/or which may form nodular lymphoid aggregates with or without germinal centers.

As in any classification system, the 2002 ATS/ERS international multidisciplinary consensus classification of the IIPs[3] included an unclassifiable interstitial pneumonia category for cases that could not be classified for various reasons: inadequate clinical or radiologic information; inadequate biopsy; major discrepancies between clinical radiologic and pathologic findings; and/or major discrepancies with histologic findings among multiple biopsies from the same case.

DIAGNOSIS BY MULTIDISCIPLINARY DISCUSSION

Clearly, a pathologic classification of IIPs cannot stand alone; thus, clinicians and radiologists alike now widely accept the fact that the diagnosis and management of the IIPs specifically require clinical-radiologic-pathologic corre-

Table 2. American Thoracic Society/European Respiratory Society 2002 International Multidisciplinary Consensus Classification of the Idiopathic Interstitial Pneumonias[a]

Histologic Pattern	Clinical-Radiologic-Pathologic Diagnosis
Usual interstitial pneumonia	Idiopathic pulmonary fibrosis or cryptogenic fibrosing alveolitis
Nonspecific interstitial pneumonia	Nonspecific interstitial pneumonia (provisional)
Organizing pneumonia	Cryptogenic organizing pneumonia
Diffuse alveolar damage	Acute interstitial pneumonia
Respiratory bronchiolitis	Respiratory bronchiolitis interstitial lung disease
Desquamative interstitial pneumonia	Desquamative interstitial pneumonia
Lymphoid interstitial pneumonia	Lymphoid interstitial pneumonia

[a] Data adapted from American Thoracic Society; European Respiratory Society.[3] American Thoracic Society/European Respiratory Society international multidisciplinary consensus classification of the idiopathic interstitial pneumonias. *Am J Respir Crit Care Med*. 2002;165(2):277–304.

Downloaded from https://aplm.kglmeridian.com at 2026-03-06 via free access

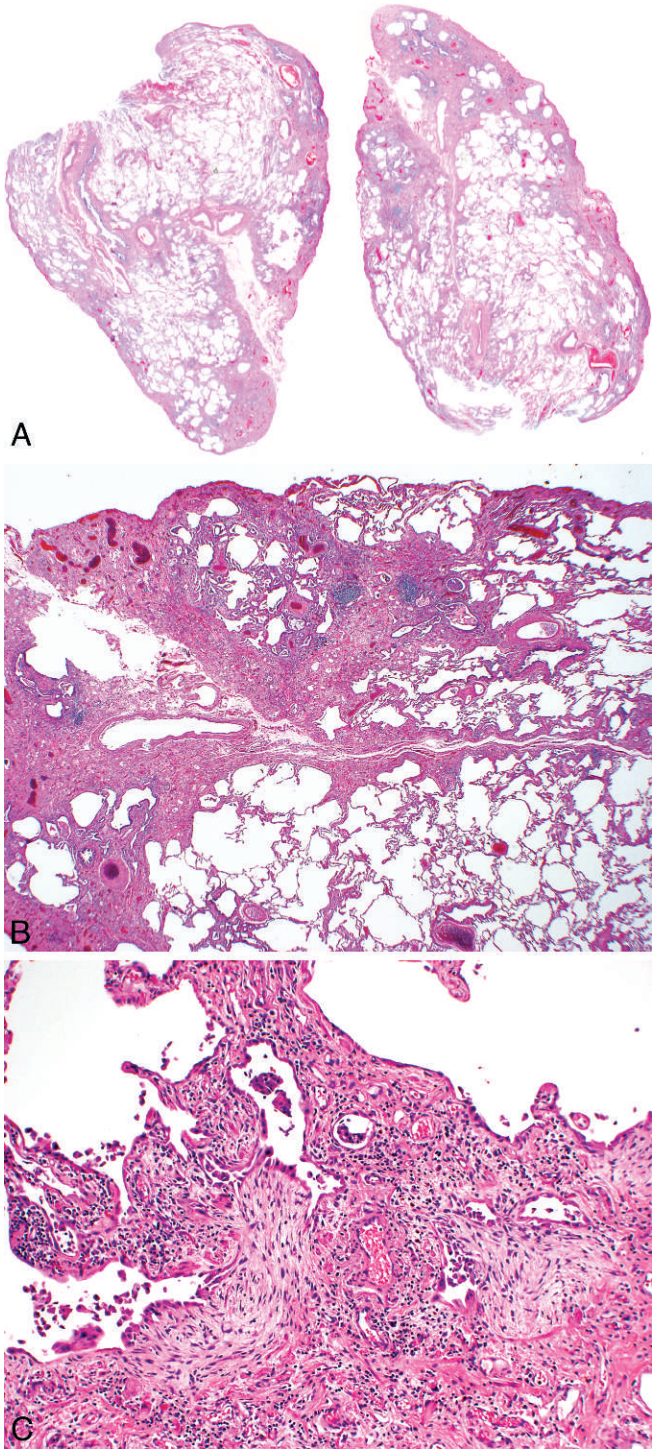

Figure 1. *Histopathologic features of usual interstitial pneumonia. A, Histologic appearance is heterogeneous, with areas of fibrosis (scarring and honeycomb) amid less affected parenchyma. B and C, Active disease contains scattered fibroblast foci: subepithelial foci of proliferating fibroblasts and myofibroblasts (hematoxylin and eosin; scanning power [A], low power [B], and intermediate power [C] magnifications).*

lation with multidisciplinary discussion (MDD),[3,5–7] or by a multidisciplinary team. At the same time, current medical practice dictates that clinical practice guidelines must be founded on a rigorous assessment of the best available clinical evidence. With this background, the 2011 ATS/ERS/JRS/ALAT evidence-based guidelines for diagnosis and management of IPF[5] include MDD as an integral component of the diagnostic process and include a rigorous evidence-based assessment of the medical literature for any diagnostic and management recommendations.[5] The pathologist must be familiar with these guidelines, especially because diagnosis of IPF now requires MDD and integration of clinical and radiologic information with histopathologic findings. Features of these consensus and guideline statements for IPF and the IIPs that are of importance to pathologists are reviewed below, beginning with the earlier guidelines that have formed the framework for pathologic diagnosis during the past decade, followed by a discussion of recent updates refining these guidelines.

Idiopathic pulmonary fibrosis was defined in the 2000 international consensus statement[4] on its diagnosis and treatment "as a specific form of chronic fibrosing interstitial pneumonia limited to the lung and associated with the histologic appearance of usual interstitial pneumonia (UIP) on surgical (thoracoscopic or open) lung biopsy."[4] In addition to the presence of UIP on surgical lung biopsy, the following additional features were required for a definitive diagnosis of IPF: (1) exclusion of other known causes of interstitial lung disease; (2) abnormal pulmonary function tests with restriction and/or impaired gas exchange; and (3) abnormalities on chest radiographs or high-resolution computed tomography (HRCT) (bibasilar reticular abnormalities with minimal ground-glass opacity).

The 2000 international consensus statement[4] included a list of major and minor criteria that could be used in the absence of a surgical lung biopsy as an alternate approach to diagnose IPF, thus circumventing an absolute requirement for biopsy. In this context, the major criteria were the same 3 criteria listed above, and all were required. In addition to these major criteria, at least 3 of the 4 following minor criteria were also required for a diagnosis of IPF: (1) age older than 50 years; (2) insidious onset of otherwise unexplained dyspnea on exertion; (3) duration of illness 3 months or longer; and (4) bibasilar inspiratory crackles.

With the recognition and acceptance of HRCT as an acceptable surrogate for surgical lung biopsy for identification of a UIP pattern, the 2011 ATS/ERS/JRS/ALAT evidence-based guidelines for diagnosis and management of IPF[5] offered a simpler and cleaner definition: "a specific form of chronic, progressive fibrosing interstitial pneumonia of unknown cause, occurring primarily in older adults, limited to the lungs, and associated with the histopathologic and/or radiologic pattern of UIP."[5] In these updated guidelines, the criteria required for a definite diagnosis of IPF required only the following: (1) exclusion of other known causes of interstitial lung disease and (2) the presence of a UIP pattern on HRCT and/or surgical lung biopsy.

Of note is that with the 2011 definition, asymptomatic patients who have normal imaging (but UIP on biopsy) can now be diagnosed as having IPF; this is important because treatment strategies and efforts to manage this condition have centered on identifying the disease at earlier stages. The diagnostic algorithm for IPF from the 2011 evidence-based guidelines is shown in Figure 2.

The 2011 evidence-based guidelines also introduced the concept of levels of confidence for a diagnosis of UIP that could be applied both to the radiologic findings and to the histopathologic findings. For patients being evaluated for suspected IPF, HRCT features are placed into 1 of 3

Downloaded from https://aplm.kglmeridian.com at 2026-03-06 via free access

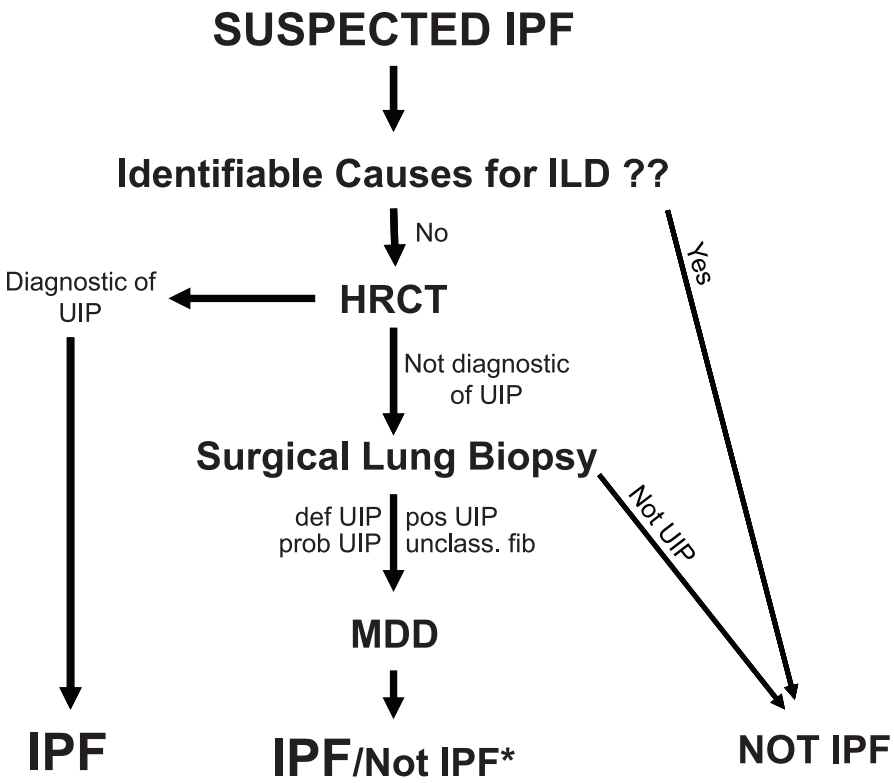

Figure 2. *2011 American Thoracic Society/European Respiratory Society/Japanese Respiratory Society/Latin American Thoracic Association diagnostic algorithm for idiopathic pulmonary fibrosis (IPF). Patients with suspected IPF should be evaluated for identifiable causes of interstitial lung disease (ILD). With no identifiable cause, high-resolution computed tomography (HRCT) showing a definite pattern of usual interstitial pneumonia (UIP) is diagnostic of IPF. With no definite UIP pattern, surgical lung biopsy can aid diagnosis in combination with imaging and histopathologic features. Multidisciplinary discussion (MDD) improves diagnostic accuracy by reconciling discordant radiologic and pathologic findings. Asterisk indicates that a decision favoring a diagnosis of IPF or non-IPF is based on MDD and Table 3. Abbreviations: def, definite; prob, probable; pos, possible; unclass fib, unclassifiable fibrosis.*

categories: definite UIP, possible UIP, or inconsistent with UIP. The criteria for these categories were based in part on radiologic studies with somewhat similar criteria. A similar schema was also devised for pathologists; its 4 categories were designed to convey the level of confidence for a histopathologic diagnosis of UIP in a patient clinically suspected to have IPF, although the criteria were not based on any validated study:

Definite UIP (all 4 of these 4 criteria): (1) marked fibrosis or architectural distortion with or without honeycombing in a predominantly subpleural or paraseptal distribution; (2) patchy involvement of lung parenchyma by fibrosis; (3) presence of fibroblast foci; and (4) absence of features against a diagnosis of UIP suggesting an alternate diagnosis, that is, "not UIP." (See "not UIP" below.)

Probable UIP: (1) marked fibrosis or architectural distortion with or without honeycombing; (2) absence of either patchy involvement or fibroblastic foci, but not both; or (3) absence of features against a diagnosis of UIP suggesting an alternate diagnosis (see "not UIP" below); OR honeycomb changes only.

Possible UIP (all 3 of these 3 criteria): (1) patchy or diffuse involvement of lung parenchyma by fibrosis, with or without interstitial inflammation; (2) absence of other UIP criteria (see "definite UIP" above); and (3) absence of features against a diagnosis of UIP suggesting an alternate diagnosis (see "not UIP" below).

Not UIP (any of these 6 criteria): (1) hyaline membranes; (2) organizing pneumonia; (3) granulomas; (4) marked interstitial inflammatory infiltrate away from honeycombing; (5) predominant airway-centered changes; or (6) other features suggestive of an alternate diagnosis.

(See acute exacerbation of IPF below.)

According to the 2011 evidence-based guidelines, the radiologic and pathologic interpretations and confidence levels should be combined in a grid to aid the clinician in determining whether IPF is present (Table 3). In this scheme, MDD represents the primary mode of reconciliation for cases in which the radiologic and pathologic diagnoses are substantially discordant.

The histopathologic criteria or confidence levels in the 2011 evidence-based guidelines have not been validated prospectively and are not based on any specific studies but instead represent an initial attempt by experts to address levels of confidence in the recognition of UIP, primarily for defining acceptable criteria for inclusion of patients in clinical treatment trials. Even casual observers know that UIP may occasionally include a focus of organizing pneumonia, areas of airway scarring with peribronchiolar metaplasia, scattered foci of increased inflammation, or any combination of these. However, when such focal changes remain minor, the diagnosis of UIP would likely not be excluded. In honeycombing in UIP, for example, a giant cell (granulomatous) reaction to cholesterol is common, so when granulomas are listed as a "not UIP" feature, that criterion specifically refers to sarcoidlike granulomas. But should 1 sarcoidlike granuloma, identified on 1 of 20 otherwise typical slides, exclude a diagnosis of UIP? There are no guidelines defining how extensive these "not UIP" changes should be before a case is truly not UIP. The answers to these questions are unknown and may never be answered rigorously, but it is important for the issues to at least be raised and for pathologists to be aware of them.

Practically speaking, the above criteria for diagnosis of definite, probable, or possible UIP, and for "not UIP," allow a relatively homogeneous set of cases to be categorized as definite UIP, thereby producing a relatively clean population for clinical trials. Cases in the probable and possible categories are less common; likewise, from our perspective, cases of not UIP are also relatively uncommon in patients

Downloaded from https://aplm.kglmeridian.com at 2026-03-06 via free access

Table 3. American Thoracic Society/European Respiratory Society/Japanese Respiratory Society/Latin American Thoracic Association 2011 Guidelines for Diagnosis of Idiopathic Pulmonary Fibrosis (IPF) by a Combination of High-Resolution Computed Tomography (HRCT) and Surgical Lung Biopsy, With Multidisciplinary Discussion[a]

HRCT Pattern	Surgical Lung Biopsy Pattern	Diagnosis of IPF?
UIP	UIP	Yes
	Probable UIP	Yes
	Possible UIP	Yes
	Nonclassifiable fibrosis	Yes
	Not UIP	No
Possible UIP	UIP	Yes
	Probable UIP	Yes
	Possible UIP	Probable
	Nonclassifiable fibrosis	Probable
	Not UIP	No
Inconsistent with UIP	UIP	Possible
	Probable UIP	No
	Possible UIP	No
	Nonclassifiable fibrosis	No
	Not UIP	No

Abbreviation: UIP, usual interstitial pneumonia.
[a] Data adapted from Raghu et al.[5] An official ATS/ERS/JRS/ALAT statement: idiopathic pulmonary fibrosis: evidence-based guidelines for diagnosis and management. *Am J Respir Crit Care Med*. 2011;183(6):788–824.

who come to biopsy after having been carefully and systematically evaluated clinically and radiologically for suspected IPF. The most common pattern in the probable UIP category is diffuse honeycomb change, which reflects the fact that UIP tends to be a subpleural process. When a sufficient amount of subpleural tissue is involved, even a generous wedge biopsy may show only honeycomb change.

What do these "confidence levels" for the diagnosis of UIP mean for pathologists in their routine signout of lung biopsies? Should terms such as "definite UIP," etc, be part of a pathology report? These terms might be useful if a clinical trial is a consideration for the patient, but many trials have central review of pathology where the issue is dealt with. We don't think assigning levels of confidence to a diagnosis of UIP with terms such as "definite," "probable," and "possible" is ready for prime time in the routine practice of surgical pathology. Nevertheless, it is important for the pathologist to convey some level of certainty of the diagnosis with some descriptive terminology if a straightforward diagnosis is not possible.

Another significant addition to the 2011 evidence-based guidelines for IPF[5] compared with those in the 2000 international consensus statement[4] is the acceptance of the phenomenon of acute exacerbation of IPF, in which one typically sees diffuse alveolar damage superimposed on UIP (Figure 3, A and B). This represents an acute worsening of the condition that cannot be explained by another cause such as infection, pulmonary embolus, or heart failure. The criteria include unexplained worsening of dyspnea within a month, hypoxemia, new alveolar infiltrates identified radiologically, and absence of an alternate explanation.[8] Acute exacerbation can occur any time during the course of IPF and may actually be the presenting manifestation of clinically occult disease. Recognition of acute exacerbation of IPF is important, because these patients tend to follow a more precipitous course, with high mortality, and may benefit from early and aggressive intervention. Although data are limited on treatment approaches for acute exacerbation of IPF, high-dose corticosteroids are often used with some success.[8] Acute exacerbation of IPF remains a difficult clinical problem, and trials of other pharmacologic agents have been largely disappointing.

For the pathologist, acute exacerbation typically manifests as acute and/or organizing diffuse alveolar damage superimposed on the background patchy fibrotic pattern of UIP. In some cases, the most prominent changes will be organization and/or edema of alveolar septa with type 2 cell metaplasia. Although the features of acute exacerbation (diffuse alveolar damage and/or organizing pneumonia) were considered exclusionary for the pathologic diagnosis of UIP (see criteria above), these changes may be encountered in patients with acute exacerbation of IPF, so this diagnosis is now formally included in the new guidelines. As noted above, recognition of the acute process superimposed on the chronic process is important clinically, radiologically, and pathologically.

Multidisciplinary discussion has become integral not only to the diagnosis of IPF but also to the diagnosis of other IIPs. It constitutes the dynamic interplay and exchange of ideas among various specialties, typically including pulmonologists, radiologists, and (when biopsy material has been taken) pathologists. Interestingly, the exchange of ideas and the use of clinical, radiologic, and pathologic information in the study of an individual case will lead the participants (including pathologists) to rereview and often change the diagnosis based on their initial impressions as they learn more about a case. A good example is the surgical lung biopsy that shows typical features of UIP, but is later discovered upon MDD to come from a patient with upper lobe–dominant disease radiologically and a history of bird exposure. What the pathologist might have initially thought was UIP typical of IPF would now be interpreted as UIP consistent with chronic hypersensitivity pneumonitis (ie, the same pattern with a different interpretation of its significance). Similarly, a pathologist might dismiss a rare granuloma or some prominence of centrilobular inflammation and/or fibrosis in a surgical biopsy, yet reassess these findings as potentially important if it was determined during MDD that hypersensitivity pneumonitis was in the clinical differential.

To summarize the key features for the pathologist in the 2011 evidence-based guidelines for IPF[5]: (1) Surgical lung biopsy is no longer necessary for diagnosis of IPF; HRCT is acceptable instead. (2) MDD is integral to the diagnosis and management of IPF. (3) Pathologists should attempt to assign levels of confidence to the histologic diagnosis of UIP, but these levels are not validated and should be considered more conceptual than practical. (4) Acute exacerbation of IPF is an accepted phenomenon, and acute lung injury superimposed on a patchy fibrotic UIP-like background should prompt consideration of this diagnosis. (5) "Exclusionary" histologic features for diagnosis of UIP are imprecise, and there are no guidelines that specifically define how they should be applied.

EXPECTED UPDATES TO THE CONSENSUS CLASSIFICATION OF IIPS

The 2002 multidisciplinary consensus classification of the IIPs[3] is being updated and should be available in 2012. As discussed below, some of the changes being recommended

Downloaded from https://aplm.kglmeridian.com at 2026-03-06 via free access

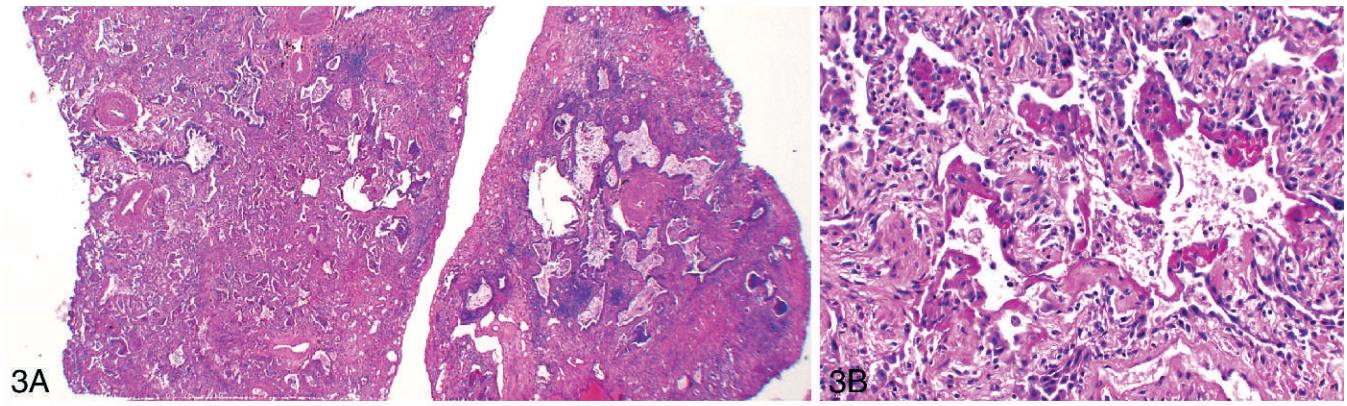

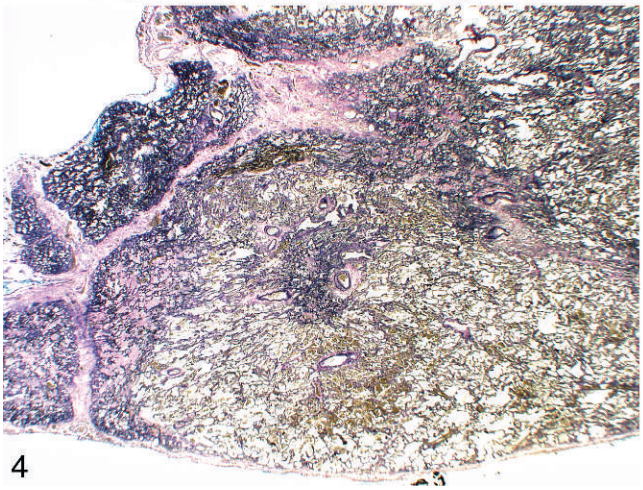

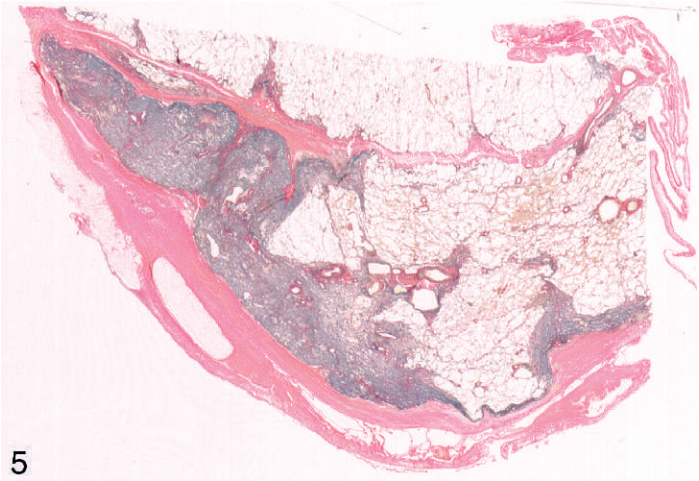

Figure 3. *Histopathologic features of acute exacerbation of idiopathic pulmonary fibrosis. A, Diffusely abnormal lung tissue with honeycombing (right) and some regions of architectural preservation (left center) showing diffuse alveolar damage. B, Hyaline membranes (hematoxylin and eosin; scanning power [A] and high power [B] magnifications).*

Figure 4. *Histopathologic features of idiopathic pleuroparenchymal fibroelastosis. This upper lobe biopsy shows marked subpleural and parenchymal fibrosis, with abundant accompanying elastic fiber deposition (elastic stain, scanning power magnification).*

Figure 5. *Histopathologic features of so-called idiopathic pulmonary upper lobe fibrosis. Areas of alveolar collapse with fibrosis and elastic fiber proliferation in a subpleural distribution are similar to idiopathic pleuroparenchymal fibroelastosis (elastic stain, scanning power magnification; image courtesy of Y. Kawabata, MD, Tokyo, Japan).*

will have implications for pathologists. In 2002, the classification included a clinicopathologic diagnosis paired with a pathologic pattern. Because a consensus statement should center on clinicopathologic diagnoses, the multidisciplinary diagnoses alone will be highlighted in the updated classification. In addition, lymphoid interstitial pneumonia is now recognized as a sufficiently rare entity and will no longer be included among the major IIPs but instead will be included in a new category of rare IIPs, along with the newly recognized idiopathic pleuroparenchymal fibroelastosis (PPFE). The expected updated classification is summarized in Table 4 as it was presented in a symposium at the ATS International Conference in Denver, Colorado on May 18, 2011. The document has recently been submitted to the ATS and ERS boards for review and approval, and is still subject to possible changes (W.D. Travis, MD, e-mail communication, March 2012).

The expected updated categorization outlined in Table 4 is similar to that in the 2002 international multidisciplinary consensus classification,[3] with the notable addition of idiopathic PPFE. This entity will be discussed further below. There is also a notable absence of bronchiolocentric interstitial pneumonias that could have been included in the update, as described in 3 separate pathologic studies of what were interpreted as IIPs with airway centering or bronchiolocentricity. These dealt with the idiopathic bronchiolocentric interstitial pneumonia,[9] airway-centered interstitial fibrosis,[10] and peribronchiolar metaplasia–associated interstitial lung disease.[11] Although these reports are intriguing, the airway-centered processes were deemed neither sufficiently distinctive nor well enough characterized for inclusion in the forthcoming revised classification. Additional studies are necessary to determine whether they truly represent distinct clinicopathologic entities.

Some key clinical messages expected in the update that could impact pathologists include statements that transbronchial biopsies are not useful in the diagnosis of most IIPs; that bronchoalveolar lavage is not useful in the diagnosis of most IIPs; and that surgical lung biopsy is most helpful when combined with clinical and radiologic data that would result in an uncertain or "not IPF" diagnosis. These statements are not surprising, given the

Downloaded from https://aplm.kglmeridian.com at 2026-03-06 via free access

Table 4. Expected Updated International Consensus Classification of Idiopathic Interstitial Pneumonias (IIPs)[a]
Major IIPs
Idiopathic pulmonary fibrosis
Idiopathic nonspecific interstitial pneumonia
Respiratory bronchiolitis-associated interstitial lung disease
Desquamative interstitial pneumonia
Cryptogenic organizing pneumonia
Acute interstitial pneumonia
Rare IIPs
Idiopathic lymphoid interstitial pneumonia
Idiopathic pleuroparenchymal fibroelastosis
Unclassifiable IIPs

[a] As presented at the American Thoracic Society International Conference in Denver, Colorado, on May 18, 2011. The consensus document has been submitted to the American Thoracic Society and European Respiratory Society boards for review and approval, and is still subject to possible changes (W.D. Travis, MD, personal communication, March 2012).

results of several large studies showing limited utility for transbronchial biopsies[12] and bronchoalveolar lavage[13–15] in patients with IPF and the recognition of HRCT as a valid alternative for surgical lung biopsy in diagnosis.[16–20]

IDIOPATHIC PPFE: A NEWLY RECOGNIZED ENTITY

Idiopathic PPFE was first mentioned in the English-language medical literature in 2004 in a small case series.[21] Another small case series[22] was published in 2008, followed by a report of 2 cases[23] in 2011. Although reports of PPFE are rare, it is being recognized as a distinct entity that may be underrecognized and underdiagnosed. Cases of PPFE display several key radiologic and pathologic features, including pleural and parenchymal opacities that are preferentially located in the upper lobes and peripherally distributed, correlating with the marked pleural and subpleural elastosis seen in biopsy material. Importantly, these histologic changes are sufficiently extensive to explain radiologic abnormalities and physiologic dysfunction in these patients. More recently, a larger series of 12 adult patients from Brompton Hospital in London[24] delineated specific features of PPFE. Of these 12 patients, 5 were aged 50 years or older, and 7 were female. Seven had a history of recurrent infections, and 2 had a history of familial interstitial lung disease. Disease progression occurred in 7 patients, and 5 died from PPFE. A case of idiopathic PPFE is illustrated in Figure 4.

We suspect that a number of cases described as idiopathic pulmonary upper lobe fibrosis in the Japanese medical literature in the 1990s represent PPFE. One such case, courtesy of Y. Kawabata, MD, in Tokyo (see Kobayashi et al[26] and Shiota et al[27]), is illustrated in Figure 5. The Japanese cases share many clinical, radiologic, and pathologic features with PPFE, including an association with spontaneous pneumothoraces, a history of familial interstitial lung disease and/or pneumothoraces, the presence of radiologic opacities that are preferentially located in the upper lobes, and surgical lung biopsy findings that include areas of alveolar collapse with fibrosis and proliferation of elastic fibers in a subpleural distribution.[25–28]

Not all cases of PPFE are idiopathic. A 2011 description[29] of 4 cases of PPFE noted that all 4 were associated with bone marrow transplantation and a history of recurrent pneumothoraces. In these cases, the time from transplantation to presentation was variable, ranging from 2 to 16 years. In addition to having subpleural and paraseptal fibroelastosis, all 4 patients displayed concomitant obliterative bronchiolitis, which suggests that PPFE may be a late complication of a chronic graft-vs-host disease, radiation effect, or chemotherapeutic drug effect.[29] Although the etiology of this unusual disorder remains poorly understood and cases are rare, inclusion of PPFE in the new classification scheme may aid its recognition, enable additional studies on its pathogenesis, and facilitate the identification of potential treatment approaches.

SUMMARY

Over the decades, IIPs have undergone reclassification that continues to evolve as our understanding of these disorders is further refined. In the past year alone, updated evidence-based guidelines for the diagnosis and management of IPF were released, and several updates to the consensus classification of IIPs are expected later this year. Many of these recent and anticipated changes are relevant to pathologists, such as the use of MDD among clinicians, radiologists, and pathologists for diagnosis of IIPs and the use of HRCT as an acceptable alternative to surgical lung biopsy for diagnosis of IPF. In addition, although the histologic diagnosis of UIP has not yet been validated, pathologists should assign levels of confidence for a histologic diagnosis. Pathologists must also learn to recognize acute exacerbation of IPF, because this entity is associated with high mortality and may require aggressive early treatment. The forthcoming updated classification of IIPs will include a separate category for rare entities such as lymphoid interstitial pneumonia and the newly recognized idiopathic PPFE. Pathologists should familiarize themselves with these new guidelines and criteria, because this understanding will be essential to effective MDD with clinical colleagues and to the selection of appropriate care for patients with IIPs.

The authors gratefully acknowledge the invaluable editorial assistance of Mary Ann Clifft MS, Jean L. Poncelet, and the Section of Scientific Publications of Mayo Clinic.

References

1. Liebow AA, Carrington CB. The interstitial pneumonias. In: Simon M, Potchen EJ, LeMay M, eds. *Frontiers of Pulmonary Radiology: Pathophysiologic, Roentgenographic and Radioisotopic Considerations: Proceedings of the Symposium Sponsored by Harvard Medical School, April 21–22, 1967*. 1st ed. New York, NY: Grune & Stratton; 1969:102–141.

2. Travis WD, Hunninghake G, King TE Jr, et al. Idiopathic nonspecific interstitial pneumonia: report of an American Thoracic Society project. *Am J Respir Crit Care Med*. 2008;177(12):1338–1347.

3. American Thoracic Society; European Respiratory Society. American Thoracic Society/European Respiratory Society international multidisciplinary consensus classification of the idiopathic interstitial pneumonias. *Am J Respir Crit Care Med*. 2002;165(2):277–304.

4. American Thoracic Society; European Respiratory Society. Idiopathic pulmonary fibrosis: diagnosis and treatment: international consensus statement. *Am J Respir Crit Care Med*. 2000;161(2, pt 1):646–664.

5. Raghu G, Collard HR, Egan JJ, et al. An official ATS/ERS/JRS/ALAT statement: idiopathic pulmonary fibrosis: evidence-based guidelines for diagnosis and management. *Am J Respir Crit Care Med*. 2011;183(6):788–824.

6. Flaherty KR, King TE Jr, Raghu G, et al. Idiopathic interstitial pneumonia: what is the effect of a multidisciplinary approach to diagnosis? *Am J Respir Crit Care Med*. 2004;170(8):904–910.

7. Flaherty KR, Andrei AC, King TE Jr, et al. Idiopathic interstitial pneumonia: do community and academic physicians agree on diagnosis? *Am J Respir Crit Care Med*. 2007;175(10):1054–1060.

8. Collard HR, Moore BB, Flaherty KR, et al. Acute exacerbations of idiopathic pulmonary fibrosis. *Am J Respir Crit Care Med*. 2007;176(7):636–643.

9. Yousem SA, Dacic S. Idiopathic bronchiolocentric interstitial pneumonia. *Mod Pathol*. 2002;15(11):1148–1153.

Downloaded from https://aplm.kglmeridian.com at 2026-03-06 via free access

10. Churg A, Myers J, Suarez T, et al. Airway-centered interstitial fibrosis: a distinct form of aggressive diffuse lung disease. *Am J Surg Pathol*. 2004;28(1):62–68.

11. Fukuoka J, Franks TJ, Colby TV, et al. Peribronchiolar metaplasia: a common histologic lesion in diffuse lung disease and a rare cause of interstitial lung disease: clinicopathologic features of 15 cases. *Am J Surg Pathol*. 2005;29(7):948–954.

12. Berbescu EA, Katzenstein AL, Snow JL, Zisman DA. Transbronchial biopsy in usual interstitial pneumonia. *Chest*. 2006;129(5):1126–1131.

13. Ohshimo S, Bonella F, Cui A, et al. Significance of bronchoalveolar lavage for the diagnosis of idiopathic pulmonary fibrosis. *Am J Respir Crit Care Med*. 2009;179(11):1043–107.

14. Kinder BW, Brown KK, Schwarz MI, Ix JH, Kervitsky A, King TE Jr. Baseline BAL neutrophilia predicts early mortality in idiopathic pulmonary fibrosis. *Chest*. 2008;133(1):226–232.

15. Kinder BW, Wells AU. The art and science of diagnosing interstitial lung diseases. *Am J Respir Crit Care Med*. 2009;179(11):974–975.

16. Mathieson JR, Mayo JR, Staples CA, Muller NL. Chronic diffuse infiltrative lung disease: comparison of diagnostic accuracy of CT and chest radiography. *Radiology*. 1989;171(1):111–116.

17. Hunninghake GW, Zimmerman MB, Schwartz DA, et al. Utility of a lung biopsy for the diagnosis of idiopathic pulmonary fibrosis. *Am J Respir Crit Care Med*. 2001;164(2):193–196.

18. Raghu G, Mageto YN, Lockhart D, Schmidt RA, Wood DE, Godwin JD. The accuracy of the clinical diagnosis of new-onset idiopathic pulmonary fibrosis and other interstitial lung disease: a prospective study. *Chest*. 1999;116(5):1168–1174.

19. Grenier P, Valeyre D, Cluzel P, Brauner MW, Lenoir S, Chastang C. Chronic diffuse interstitial lung disease: diagnostic value of chest radiography and high-resolution CT. *Radiology*. 1991;179(1):123–132.

20. Swensen SJ, Aughenbaugh GL, Myers JL. Diffuse lung disease: diagnostic accuracy of CT in patients undergoing surgical biopsy of the lung. *Radiology*. 1997;205(1):229–234.

21. Frankel SK, Cool CD, Lynch DA, Brown KK. Idiopathic pleuroparenchymal fibroelastosis: description of a novel clinicopathologic entity. *Chest*. 2004;126(6):2007–2013.

22. Becker CD, Gil J, Padilla ML. Idiopathic pleuroparenchymal fibroelastosis: an unrecognized or misdiagnosed entity? *Mod Pathol*. 2008;21(6):784–787.

23. Piciucchi S, Tomassetti S, Casoni G, et al. High resolution CT and histological findings in idiopathic pleuroparenchymal fibroelastosis: features and differential diagnosis. *Respir Res*. 2011;12:111.

24. Reddy TL, Tominaga M, Hansell DM, et al. Pleuroparenchymal fibroelastosis: a spectrum of histopathological and imaging phenotypes [published online ahead of print March 22, 2012]. *Eur Respir J*. doi:10.1183/09031936.00165111.

25. Morimoto A, Mochizuki Y, Nakahara Y, Kawamura T, Sakaki S, Kobashi Y. Case of idiopathic pulmonary upper lobe fibrosis [in Japanese]. *Nihon Kokyuki Gakkai Zasshi*. 2010;48(12):944–949.

26. Kobayashi Y, Sakurai M, Kushiya M, et al. Idiopathic pulmonary fibrosis of the upper lobe: a case report [in Japanese]. *Nihon Kokyuki Gakkai Zasshi*. 1999;37(10):812–816.

27. Shiota S, Shimizu K, Suzuki M, et al. Seven cases of marked pulmonary fibrosis in the upper lobe [in Japanese]. *Nihon Kokyuki Gakkai Zasshi*. 1999;37(2):87–96.

28. Amitani R, Niimi A, Kuse F. Idiopathic pulmonary upper lobe fibrosis (IPUF). *Kokyu*. 1992;11:693–699.

29. von der Thusen JH, Hansell DM, Tominaga M, et al. Pleuroparenchymal fibroelastosis in patients with pulmonary disease secondary to bone marrow transplantation. *Mod Pathol*. 2011;24(12):1633–1639.

Downloaded from https://aplm.kglmeridian.com at 2026-03-06 via free access